

Jurnal Biomedika dan Kesehatan

Jurnal Biomedika dan Kesehatan (J Biomedika dan Kesehat) (pISSN: 2621-539X | eISSN: 2621-5470) is a peer-reviewed journal published by the Faculty of Medicine Universitas Trisakti. Starting in 2024, JBK is a fourth-monthly (March, July, November) medical journal that publishes new research findings on a wide variety of topics of importance to biomedical science and clinical practice (Biochemistry, Epidemiology, Health Profession, Occupational Therapy, medicine, Public Health).

Since 2019, JBK has been indexed and accredited in the Science and Technology Index (SINTA) 3, by the Ministry of Research, Technology, and Higher Education Indonesia.

Each manuscript will go through a review process.

SEND ARTICLE

Imaging of Schizencephaly with Polymicrogyria on Various Magnetic Resonance Imaging (MRI) Sequences

[Home](#) / [Archives](#) / [Vol. 8 No. 1 \(2025\)](#) / [Case Report](#)

Imaging of Schizencephaly with Polymicrogyria on Various Magnetic Resonance Imaging (MRI) Sequences

Tandy Tanaji

Department of Radiology, Faculty of Medicine, Universitas Trisakti, Jakarta,
Indonesia

Farah Hendara

Department of Radiology, Faculty of Medicine, Universitas Trisakti, Jakarta,
Indonesia

Caecilia Marlina

Department of Radiology, Faculty of Medicine, Diponegoro University,
Semarang, Indonesia

Astien Astien

Department of Radiology, Faculty of Medicine, Universitas Trisakti, Jakarta,



Gupita Nareswari

Department of Radiology, Faculty of Medicine, Universitas Trisakti, Jakarta, Indonesia

Partogi Napitupulu

Department of Radiology, Faculty of Medicine, Universitas Trisakti, Jakarta, Indonesia

Mulia Rahmansyah

Department of Radiology, Faculty of Medicine, Universitas Trisakti, Jakarta, Indonesia

Revalita Wahab

Department of Radiology, Faculty of Medicine, Universitas Trisakti, Jakarta, Indonesia

DOI: <https://doi.org/10.18051/JBiomedKes.2025.v8.73-78>

Keywords:

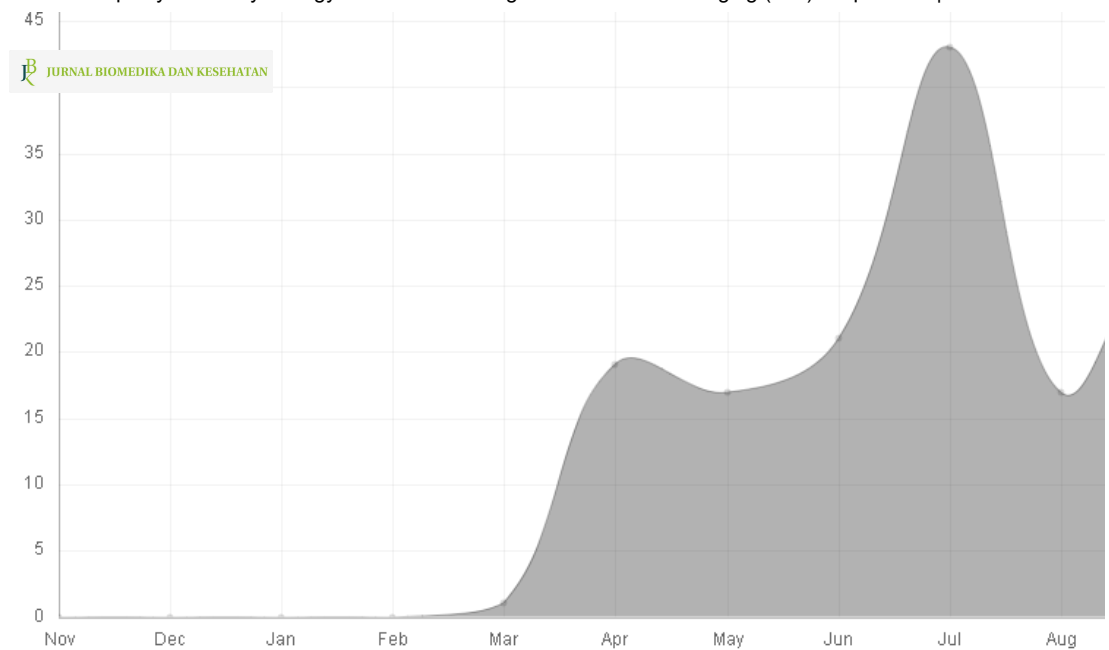
MRI, Polymicrogyria, Schizencephaly

Abstract

Schizencephaly is a rare congenital cerebral malformation within the category of neurological migration defects. Hemiparesis, developmental delays, and seizures are clinical signs that are influenced by both the size and the location of the lesion. This condition is characterized by a cleft that traverses the brain's parenchyma lined by grey-matter (transmantle cleft). In less severe cases, the cleft does not extend into the lateral ventricle. Identification of the cleft's path, accurate assessment of the cortex, and recognition of polymicrogyria are crucial for the radiological evaluation of schizencephaly.

We report a case of 18-year-old male diagnosed with closed-lip schizencephaly, which supported by MRI findings. The transmantle cleft and polymicrogyria are most effectively visualized in T2-weighted and FLAIR images. The utility of diffusion-weighted imaging (DWI) and apparent diffusion coefficient (ADC) sequences as well as susceptibility-weighted imaging (SWI) sequence in the context of schizencephaly currently remains uncertain, however it may be useful for ruling out other abnormalities such infarct, hemorrhagic, tumors or other vascular abnormalities. In this context, we emphasize the significance of MRI examination for diagnosing this condition and for recognizing the related abnormalities.

Downloads



PDF

Published
2025-03-27

How to Cite

Tanaji T, Hendara F, Marlina C, Astien A, Nareswari G, Napitupulu P, Rahmansyah M, Wahab R. Imaging of Schizencephaly with Polymicrogyria on Various Magnetic

Resonance Imaging (MRI) Sequences. J Biomedika dan Kesehat [Internet]. 2025 Mar. 27

Available from:
JURNAL BIOMEDIKA DAN KESEHATAN
php/jbk/article/view/679

More Citation Formats

Issue


Vol. 8 No. 1 (2025)

Section

Case Report

License

Copyright (c) 2025 Tandy Tanaji



This work is licensed under a [Creative Commons Attribution-NonCommercial 4.0 International License](#).

The journal allow the authors to hold the copyright without restrictions and allow the authors to retain publishing rights without restrictions.

Most read articles by the same author(s)

- Bayan Basalamah, Balqis Khansa Nabila, Yudhisman Imran, Mulia Rahmansyah, [Spondilitis tuberkulosis: perbaikan yang signifikan setelah intervensi dini](#) , Jurnal Biomedika dan Kesehatan: Vol. 3 No. 3 (2020)
- Rima Anindita Primandari, Mulia Rahmansyah, Rima Mustafa, [Radikulomielopati servikal pascatrauma: laporan kasus](#) , Jurnal Biomedika dan Kesehatan: Vol. 4 No. 3 (2021)
- Revalita Wahab, Purnamawati Tjhin, [Program remedial dan angka putus studi mahasiswa kedokteran](#) , Jurnal Biomedika dan Kesehatan: Vol. 4 No. 2 (2021)
- Rima Januaristi, Revalita Wahab, [Hubungan e-cigarettes dan risiko cardiovascular disease pada usia 25-65 tahun](#) , Jurnal Biomedika dan Kesehatan: Vol. 1 No. 1 (2018)
- Astien Astien, Nany Hairunisa, Nugroho Abikusno, Revalita Abikusno, Nadifa Agil, Febrina T, [Metachronous Multifocal Osteosarcoma After 5-month Therapy: Metastasis or Other Primary Lesion?](#) , Jurnal Biomedika dan Kesehatan: Vol. 6 No. 3 (2023)
- Ifan Aji Darmawan, I Putu Eka Juliantara, Langkir Sapto Adi, Astien Astien, Revalita Wahab, [Analysis of the Effective Dose of Non-Contrast Head CT-Scan Examination Base on Gender Using the Radiation Dose Calculator at Hermina Bitung Hospital Analisis Dosis](#) , Jurnal Biomedika dan Kesehatan: Vol. 7 No. 3 (2024)



Jurnal Biomedika dan Kesehatan (JBK) is licensed under a [Creative Commons Attribution-NonCommercial 4.0 International License](#).

222106 [View My Stats](#)

Vol. 8 No. 1 (2025)

[Home](#) / [Archives](#) / Vol. 8 No. 1 (2025)



DOI: <https://doi.org/10.18051/JBiomedKes.2025.v8.i1>

Published: 2025-03-27



Human Metapneumovirus (hMPV): A New Challenge in Global Health

Rita Khairani

1-5

 PDF

Original Article



Influence of Balancing Exercises on Postural Balance in the Elderly

Fauzyah Azzahra Widiyanta, Nuryani Sidarta

6-13

 PDF

Right Ventricular Systolic Function Difference between Pulmonary Arterial Hypertension and Pulmonary Venous Hypertension

Vito Rayhansyah, Mefri Yanni, Miftah Irramah, Rita Hamdani, Gusti Revilla, Linosefa Linosefa

14-25

 PDF

Association between Anthropometric Measurements and Metabolic Syndrome in Office Workers in Trisakti University: A Cross-Sectional Study

Antin Trilaksmi, Diani Nazma, Christian Soesilo, Meiriani Sari, Karlina Mahardieni, Lira Panduwati

26-34

 PDF

In-vitro Comparative Study of Anthelmintic Efficacy of *Centella asiatica* and *Mimosa pudica* Against *Ascaris suum*

Cliffton Cliffton, Evi Ulina Margareta Situmorang, Rita Dewi, Freggy Spicano Joprang

35-44



Comparison of Biometric Measurements and Visual Acuity in Pediatric Cataract Patients Before and After Cataract Surgery

Meiliana Angeline Uirianto, Anne Umboh, Laya Rares, Riani Witjaksana

45-54



Hemolysis Rate of Packed Red Cells Products from Obese Donors

Dyah Artini, Dwi Eni Danarsih, Nur'Aini Purnamaningsih

55-63



Effectiveness of Administering Probiotic Bifidobacterium Longum on the Growth of Pseudomonas aeruginosa in Mice (Mus musculus)

Adrian Adrian, Edward Pandu Wiriansya, Dzul Ikram, Amrizal Muchtar, Suci Noviyannah Anshary, Marzelina Karim, Fazdlurrahman Fazdlurrahman, Izhar Fitrah Ahmad, M. Fathir Faisal, Muh. Muflih Usman, Muhammad Ilham

64-72



Case Report



Imaging of Schizencephaly with Polymicrogyria on Various Magnetic Resonance Imaging (MRI) Sequences

Tandy Tanaji, Farah Hendara, Caecilia Marlina, Astien Astien, Gupita Nareswari, Partogi Napitupulu, Mulia Rahmansyah, Revalita Wahab

73-78



The Effectiveness of Soursop Leaf Extract (*Annona muricata* L) in Breast Cancer Therapy Through the Apoptosis Pathway

Nadhira Tsurayya Ramadhani, Putri Maharani, Shafira Wahono, Tasya Aulia Maharani, Masayu Syarinta Adenina

79-86

 PDF

Efficacy of Botulinum Toxin Type A (BTX-A) Injection for the Treatment of Postherpetic Neuralgia: A Literature Review

Edward Wijaya, Ketut Kwartantaya Winaya, Desak Nyoman Trisepti Utami

87-97

 PDF

Definition of Microsatellite Instability in cancer: what should you know?

Mays Talib Abdallah, Ola E Al-Shakarchi, Asmaa A Hussein, Mohammed Essam Abdulmuttaleb, Ahmed Zuhair Alsammarraie, Ismail H Aziz, Noor Jabbar Dawood, Mohammed Kadhom

98-110

 PDF



Jurnal Biomedika dan Kesehatan (JBK) is licensed under a Creative Commons

Attribution-NonCommercial 4.0 International License.

222103 [View My Stats](#)

© Platform & Workflow by: Open Journal Systems
Designed by Material Theme

Editorial Team

[Home](#) / Editorial Team

Editorial Team

Editor in Chief

Husnun Amalia

Fakultas Kedokteran Universitas Trisakti, Indonesia

Academic profile:     

Deputy Editor-in-Chief

Nany Hairunisa

Fakultas Kedokteran Universitas Trisakti, Indonesia

Academic profile:     

Rivo Mario Warouw Lintuuran

Fakultas Kedokteran Universitas Trisakti, Indonesia

Academic profile:   

Magdalena Wartono

Fakultas Kedokteran Universitas Trisakti, Indonesia

Academic profile:

Editorial Boards**Raditya Wratsangka**

Fakultas Kedokteran Universitas Trisakti, Indonesia

Academic profile:     

Monica Dwi Hartanti

Fakultas Kedokteran Universitas Trisakti, Indonesia

Academic profile:     

Siti Sugih Hartiningsih

STIKes Dharma Husada Bandung, Indonesia

Academic profile:     

Dito Anugroho

Universitas Muhammadiyah (Unismuh) Makassar, Indonesia

Academic profile:     

Emad Yousif

Department of Chemistry, College of Science, Al-Nahrain
University, Baghdad, Iraq





Academic profile:  

Norsuhana Omar




Department of Physiology & Unit of Integrative Medicine,
School of Medical Sciences, Universiti Sains Malaysia (USM),
Kelantan, Malaysia

Academic profile:  



Seçil KARAHÜSEYİN

Department of Pharmacognosy,
 **JURNAL BIOMEDIKA DAN KESEHATAN** ukurova University
Balcali, 01330, Adana, Türkiye
Academic profile:   



Mohd Shahrulsalam Mohd Shah

Department of Surgery,
School of Medical Sciences, Universiti Sains Malaysia (USM),
Kelantan, Malaysia
Academic profile:   




Fithri Indraswari

Department of Pediatrics, Klinikum Fulda,
Universitätsmedizin Philipps-Universität-Marburg –
Campus Fulda - 36043 Fulda - Germany
Academic profile:  

Pravina Shantira Shagar

Menzies School of Health Research, Charles Darwin University
Casuarina campus, Australia
Academic profile:  

Noureddine Djebli

Department of Biology, Faculty of SNV,
Mostaganem University
Mostaganem 27000 - ALGERIA
Academic profile:   

Editorial Office



Jurnal Biomedika dan Kesehatan (JBK) is licensed under a Creative Commons

Attribution-NonCommercial 4.0 International License.

222102 [View My Stats](#)

© Platform & Workflow by: Open Journal Systems

Designed by Material Theme

CASE REPORT

Imaging of Schizencephaly with Polymicrogyria on Various Magnetic Resonance Imaging (MRI) Sequences

Gambaran Schizencephaly dengan Polymicrogyria pada Berbagai Magnetic Resonance Imaging (MRI) Sekuens


Tandy Tanaji¹, Farah Hendara², Caecilia Marlina³, Astien¹, Gupita Nareswari¹, Partogi Napitupulu¹, Mulia Rahmansyah¹, Revalita Wahab¹

¹Department of Radiology, Faculty of Medicine, Universitas Trisakti, Jakarta, Indonesia

²Department of Radiology, Faculty of Medicine, Diponegoro University, Semarang, Indonesia

³Department of Radiology, Columbia Asia Hospital, Jakarta, Indonesia

tandy.chintya@trisakti.ac.id

 <https://doi.org/10.18051/JBiomedKes.2024.v8.73-78>

ABSTRACT

Schizencephaly is a rare congenital cerebral malformation within the category of neurological migration defects. Hemiparesis, developmental delays, and seizures are clinical signs that are influenced by both the size and the location of the lesion. This condition is characterized by a cleft that traverses the brain's parenchyma lined by grey-mater (transmantle cleft). In less severe cases, the cleft does not extend into the lateral ventricle. Identification of the cleft's path, accurate assessment of the cortex, and recognition of polymicrogyria are crucial for the radiological evaluation of schizencephaly.

We report a case of 18-year-old male diagnosed with closed-lip schizencephaly, which supported by MRI findings. The transmantle cleft and polymicrogyria are most effectively visualized in T2-weighted and FLAIR images. The utility of diffusion-weighted imaging (DWI) and apparent diffusion coefficient (ADC) sequences as well as susceptibility-weighted imaging (SWI) sequence in the context of schizencephaly currently remains uncertain, however it may be useful for ruling out other abnormalities such as infarct, hemorrhagic, tumors or other vascular abnormalities. In this context, we emphasize the significance of MRI examination for diagnosing this condition and for recognizing the related abnormalities.

Keywords: MRI; Polymicrogyria; Schizencephaly.

ABSTRAK

Schizencephaly merupakan kelainan kongenital malformasi otak langka yang terjadi akibat gangguan tahap migrasi neuronal. Hemiparesis, gangguan tumbuh kembang, dan kejang merupakan tanda klinis yang dipengaruhi oleh besarnya ukuran dan lokasi dari lesi. Schizencephaly ditandai dengan adanya celah yang melintasi parenkim otak yang terbungkus oleh grey-matter. Pada kasus ringan, celah tidak sampai masuk ke dalam ventrikel lateral. Penilaian yang akurat mengenai bentuk korteks, identifikasi jalur celah, dan temuan polimikrogria sangat penting untuk menegaskan diagnosis schizencephaly secara radiologis.

Kami melaporkan kasus seorang remaja laki-laki berusia 18 tahun dengan close-lip schizencephaly, diagnosa ditegakkan dengan bantuan pemeriksaan MRI. Temuan celah yang melintasi parenkim otak

dan polimikrogyria pada MRI, tervisualisasi secara jelas pada sekuens T2WI dan FLAIR. Peran diffusion-weighted imaging (DWI), koefisien difusi semu (ADC), dan susceptibility-weighted imaging (SWI) dalam menegaskan diagnosa schizencephaly masih belum pasti, namun mungkin berguna untuk menyingkirkan kelainan dengan tanda klinis serupa, seperti infark, perdarahan, tumor, maupun kelainan vaskuler lainnya. Dalam laporan kasus ini, kami menekankan pentingnya pemeriksaan MRI dalam menegaskan diagnosa serta mengenali kelainan terkait lainnya.

Kata Kunci: MRI; Polymicrogyria; Schizencephaly.

INTRODUCTION

Schizencephaly is a rare cortical malformation in the form of a cleft that is seen throughout the brain parenchyma.¹ It is defined by a cleft that spans the entire cerebral hemisphere from the lateral ventricle to the cerebral cortex.² The margins of the cleft are lined with heterotrophic, dysplastic gray matter extending from the cortex to the ventricular surface with intact pia and ependyma.^{3,4} It is thought to affect 0.54-1.54 out of every 100,000 live births and is detected in childhood; it's extremely rare to go unnoticed.^{5,6} There are two types of schizencephaly, in type I (closed-lip), the walls of the cleft are closely apposed thus obliterating the CSF space within the cleft, while in type II (open-lip), the cleft walls are separated with CSF filling the cleft and extending from the ventricle to the subarachnoid space.^{7,8}

Polymicrogyria is a malformation of cortical development characterized by overfolding and abnormal lamination of the cerebral cortex.⁹ The etiopathogenesis of Schizencephaly has not been clearly understood;¹⁰ however, studies demonstrate multiple possible etiologies ranging from intrauterine insult to possible genetic etiology.¹¹

Magnetic resonance imaging is central to the diagnosis of children with congenital brain abnormalities, especially Schizencephaly.¹² Identification of the cleft's path, accurate assessment of the cortex, and recognition of polymicrogyria are crucial for the radiological evaluation of schizencephaly, to differentiate it from heterotopias and focal cortical dysplasia.¹

Previously, very few cases reported about schizencephaly in adolescence and polymicrogyria altogether on MRI have been reported; therefore, due to its rarity, we decided to make it a case report.

CASE REPORT

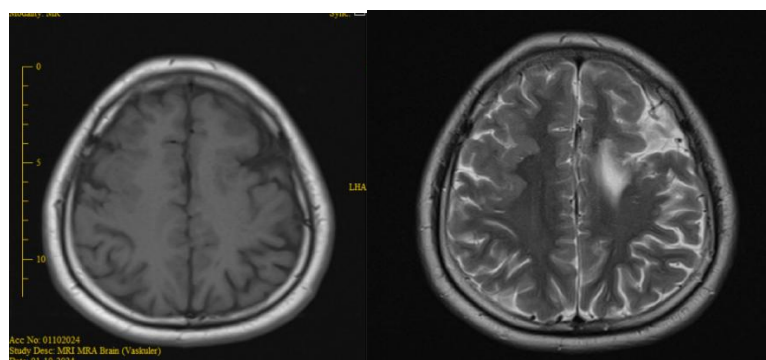
An 18-year-old male presented to the outpatient department post-seizures. Upon examination it is known that he is mentally retarded and had history of recurrent seizures since childhood for which he was under antiepileptic medication (Divalproate) but was poorly controlled. The necessary investigations regarding the seizure case were not conducted previously. There was no significant family history of neurological or psychiatric disorders, with no notable family background of neurological or psychiatric conditions. The history of birth-related injuries or maternal use of any medications during pregnancy was unrecorded. The patient does not smoke, does not consume alcohol, and reports no history of using recreational drugs.

Physical examination reveals no signs of distress with normal vital signs. Neurological examination found amblyopia and esotropia in his right eye, with a smaller head size (microcephaly). No other motor or sensory weakness was found. Laboratory tests show normal findings, and an MRI was requested.

A closed-lip appearance was observed with the cleft lined by gray matter extending from the left frontal lobe and terminating just before it enters the left lateral ventricle. It was separated by a thin sheet of ependymal layer from the lateral convexity of the left ventricle, which was visualized as hypointense on T1WI and hyperintense on T2WI. In the FLAIR sequences, the MRI signal in the cleft space was suppressed, indicating that the fluid indeed was cerebrospinal. Grey-white matter differences were better evaluated in the FLAIR sequences compared to other sequences. The cortical micro-irregularities and thickening of the cortex (polymicrogyria) in the right frontal lobe are better visualized on T2WI.

No evidence of a susceptibility effect was found on the SWI (combined post-processed magnitude and phase) or MIP (minimum intensity projection) images. There was also no diffusion restriction seen on DWI/ADC sequences, while the vascular structures were unremarkable on MRA/MRV, hence, no other abnormalities such as infarct, bleeding, and vascular malformation were noted, and MRI findings were compatible with closed-lip type schizencephaly with polymicrogyria.

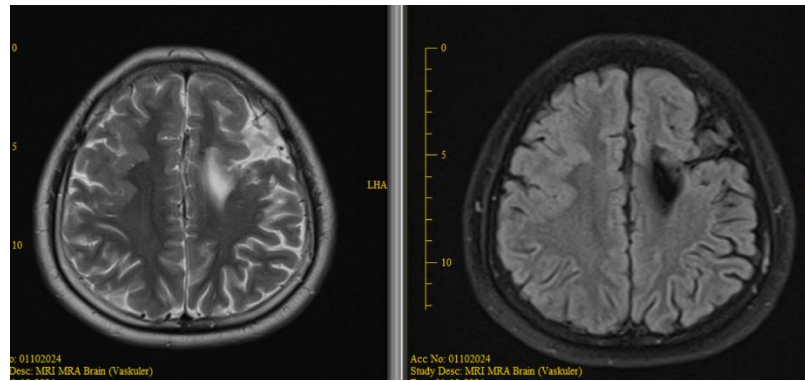
Currently patient was maintained with anti epileptic medication (Divalproex) and was suggested to visit doctors every once a month.



(a)

(b)

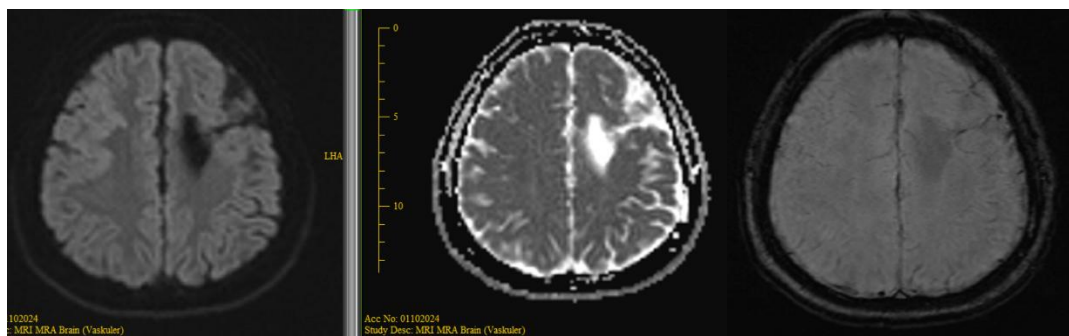
Figure 1. Cortical thickening (Polymicrogyria) is seen in the right frontal lobes on axial T1 sequence (a), however, it is best seen on axial T2WI sequence (b).



(a)

(b)

Figure 2. CSF-filled cleft lined by gray matter extending from the left frontal lobe, terminating just before it enters the left lateral ventricle (type I Schizencephaly), cleft appears hyperintense on T2 (a) and suppressed on FLAIR (b).



(a)

(b)

(c)

Figure 3. Transmantle cleft seen on DWI (a), ADC (b), and SWI (c).

DISCUSSION

Schizencephaly is classified as a rare congenital cerebral malformation defined by a cleft lined by gray matter that spans the entire cerebral hemisphere from the lateral ventricle to the cerebral cortex. It was previously reported by Zhou et. al, Griffiths, and Foram about Schizencephaly that is usually detected in neonates and childhood, with mostly being type II.^{4,10,12} However, in our case, the patient is 18 years old (age of adolescence), and upon MR Imaging we found that the cleft was not seen connecting lateral ventricle with subarachnoid spaces, as it is separated by thin-sheet of ependymal layer from the lateral wall of the left ventricle, hence it was regarded as type I.

Schizencephaly sometimes exists alone and is commonly associated with other cerebral anomalies like the absence of the septum pellucidum, as reported in separate cases by Doğan and Khadka. Doğan presented a case of schizencephaly with no other companion findings, while Khadka reported a case of schizencephaly with the absence of septum pellucidum.^{1,5} However, different from Doğan and Khadka, we reported a case of schizencephaly with another rare abnormality that is polymicrogyria.

In this case, we used MRI with different sequences, such as T1/T2-weighted images, FLAIR, SWI, DWI/ADC, MRA, and MRV to evaluate brain parenchyma and its vascularities. A closed-lip

appearance was observed with the curvilinear cleft lined by gray matter extending from the subarachnoid of the left frontal area, crossing the frontal lobe, and terminating just before it enters the left lateral ventricle. It was separated by a thin sheet of ependymal layer from the lateral convexity of the left ventricle. T1WI can depict perfectly that it is gray matter (cortex) which lines the cleft, however, the appearance of polymicrogyria, which appears as an arc of thick cortex with microirregularities, is best seen in T2WI (Fig. 1). T2WI on axial plane can show transmantle clefts filled with hyperintense cerebrospinal fluid (CSF) signal, which was suppressed (hypointense) on FLAIR. (Fig. 2). FLAIR is very valuable in evaluating schizencephaly, as it can differentiate from focal cortical dysplasia due to its hyperintensity FLAIR signal in white-matter, with or without transmantle sign, There is no abnormal signals visualized on SWI (Fig. 3), this sequence is superior in depicted blood content and calcification, its absence can exclude the possibility of other disease association such as bleed. There was no restricted diffusion on DWI/ADC (Fig. 3), which can exclude other possibilities such as infarct and infection. MRA and MRV found unremarkable visualization of brain vessels, thus excluding vascular malformation. Hence, we came out with the diagnosis of type I Schizencephaly with polymicrogyria.

CONCLUSION

We report a rare combination of type I Schizencephaly in adolescence and Polymicrogyria case, with MRI being the best imaging modality to evaluate these malformations. Every MRI sequence has different utilities according to the structures we wish to evaluate. T1WI, T2WI, and FLAIR sequences were useful to evaluate schizencephaly, with best visualization of gray-white matter differentiation seen on T1WI and FLAIR, but the cleft is best seen on T2WI. Flair is also the best sequence to confirm whether the fluid within the cleft was indeed CSF. T1 and T2 are the chosen sequences for evaluating polymicrogyria, and T2W1 in axial and sagittal planes are the best to evaluate the septum pellucidum. Other sequences, such as DWI/ADC and MRA/MRV, benefit in schizencephaly and polymicrogyria remain unclear, however, it may be useful to exclude the presence of other abnormalities, such as vascular malformation, infarct, calcifications, and hemorrhage.

ACKNOWLEDGEMENT

None.

AUTHORS CONTRIBUTION

All authors contributed to this article.

FUNDING

This case report is not funded by any institution.

CONFLICT OF INTEREST

The authors declared no conflict of interest related to this article.

REFERENCES

1. Doğan, Emran. The Evaluation of Unilateral Closed-Lip Schizencephaly on Complex MRI Sequences. *Romanian Journal of Neurology*. 2021;20(2):250-4. doi:10.37897/RJN.2021.2.21
2. Laasri K, Naggar A, El Houss S, Halfi MI, et al. Schizencephaly: A rare cause of late-onset epilepsy in an adult. *Radiol Case Rep*. 2023;18(11):3861-3864. doi:10.1016/j.radcr.2023.08.014
3. Halabuda A, Klasa L, Kwiatkowski S, et al. Schizencephaly: Diagnostics and Clinical Dilemmas. *Child's Nerv Syst*. 2015;31(4):551-6. doi: 10.1007/s00381-015-2638-1. Epub 2015 Feb 18.
4. Zhou Y, Liu L, Shen X, et al. A Case of Unilateral Closed-lip Schizencephaly Combined with Hypomyelination In a Neonate. *Research Square* 2023;1-9. doi:10.21203/rs.3.rs-2711185/v1
5. Khadka C, Gupta U, Bhandari P, et al. A case of closed lip schizencephaly with absent septum pellucidum in an adult presenting with seizure disorder. *Clin Case Rep*. 2023;11(6):e7536. doi: 10.1002/ccr3.7536.
6. Mousa AH, Abuanza IAM, Al-Olama M. Frontal lobe closed-lip schizencephaly as an atypical cause of adult-onset seizures. *Radiology Case Reports*. 2024;19(11). doi: 10.1016/j.radcr.2024.07.046
7. Okunlola AI, Olowoyo P, Okunlola C, et al. Adult-Onset Seizure Disorder Secondary to Schizencephaly. *Asian J Neurosurg*. 2020;15(1):159-61. doi: 10.4103/ajns.AJNS_293_19.
8. Ugboma EW, Agi CE. Schizencephaly: A case report and review of literature. *Niger Postgrad Med J*. 2016;23(1):38-40. doi: 10.4103/1117-1936.180181.
9. Stutterd C, Brock S, Stouffs K, et al. Genetic heterogeneity of polymicrogyria: study of 123 patients using deep sequencing. *Brain Communications*. 2021;3(1):fcaa221. doi: <https://doi.org/10.1093/braincomms/fcaa221>
10. Gala F, Pati S. Bilateral closed lip schizencephaly. *EURORAD*.2016. doi: 10.1594/EURORAD/CASE.13486.
11. Ghosn Y, Kamareddine MH, Adem C, et al. A Patient with Schizencephaly and Agenesis of Corpus Callosum with No Neurological Deficits. *J Neurosci Rural Pract*. 2018;9(3):404-5. doi: 10.4103/jnpr.jnpr_564_17.
12. Griffiths PD. Schizencephaly revisited. *Neuroradiology*. 2018;60(9):945-60. doi: 10.1007/s00234-018-2056-7.



This work is licensed under a Creative Commons Attribution Non-Commercial 4.0 International License

SERTIFIKAT

Direktorat Jenderal Pendidikan Tinggi, Riset dan Teknologi
Kementerian Pendidikan, Kebudayaan, Riset dan Teknologi Republik Indonesia



Kutipan dari Keputusan Direktorat Jenderal Pendidikan Tinggi, Riset dan Teknologi
Kementerian Pendidikan, Kebudayaan, Riset, dan Teknologi Republik Indonesia

Nomor 164/E/KPT/2021
Peringkat Akreditasi Jurnal Ilmiah Periode 2 Tahun 2021

Nama Jurnal Ilmiah
Jurnal Biomedika dan Kesehatan
E-ISSN: 26215470
Penerbit: Universitas Trisakti

Ditetapkan Sebagai Jurnal Ilmiah

TERAKREDITASI PERINGKAT 3

Akreditasi Berlaku selama 5 (lima) Tahun, yaitu
Volume 2 Nomor 1 Tahun 2019 Sampai Volume 6 Nomor 2 Tahun 2023

Jakarta, 27 December 2021
Plt. Direktur Jenderal Pendidikan Tinggi,
Riset, dan Teknologi



Prof. Ir. Nizam, M.Sc., DIC, Ph.D., IPU, ASEAN Eng
NIP. 196107061987101001



JURNAL BIOMEDIKA DAN KESEHATAN

UNIVERSITAS TRISAKTI

P-ISSN : 2621539x <> E-ISSN : 26215470 Subject Area : Health, Science



0.411765
Impact



1794
Google Citations



Sinta 3
Current Accreditation

Google Scholar Garuda Website Editor URL

History Accreditation

2019 2020 2021 2022 2023 2024 2025 2026

Garuda Google Scholar

Perbedaan Fungsi Sistolik Ventrikel Kanan antara Hipertensi Arteri Pulmonal dan Hipertensi Vena Pulmonal

Fakultas Kedokteran Universitas Trisakti Jurnal Biomedika dan Kesehatan Vol 8 No 1(2025) 14-25

2025 DOI: 10.18051/JBiomedKes.2025.v8.14-25 Accred : Sinta 3

Perbandingan Hasil Biometri dan Tajam Penglihatan pada Katarak Anak, Sebelum dan Sesudah Operasi Katarak

Fakultas Kedokteran Universitas Trisakti Jurnal Biomedika dan Kesehatan Vol 8 No 1(2025) 45-54

2025 DOI: 10.18051/JBiomedKes.2025.v8.45-54 Accred : Sinta 3

Pengaruh Latihan Keseimbangan Terhadap Keseimbangan Postural pada Lansia

Fakultas Kedokteran Universitas Trisakti Jurnal Biomedika dan Kesehatan Vol 8 No 1(2025) 6-13

2025 DOI: 10.18051/JBiomedKes.2025.v8.6-13 Accred : Sinta 3

Hubungan Antropometri dengan Sindrom Metabolik pada Pekerja Kantor di Universitas Trisakti: Studi Potong Lintang

Fakultas Kedokteran Universitas Trisakti Jurnal Biomedika dan Kesehatan Vol 8 No 1(2025) 26-34

2025 DOI: 10.18051/JBiomedKes.2025.v8.26-34 Accred : Sinta 3

Keefektifan Injeksi Toksin Botulinum Tipe A (BTX-A) untuk Terapi Neuralgia Pasca Herpes: Sebuah Tinjauan Pustaka

Fakultas Kedokteran Universitas Trisakti Jurnal Biomedika dan Kesehatan Vol 8 No 1(2025) 87-97

2025 DOI: 10.18051/JBiomedKes.2025.v8.87-97 Accred : Sinta 3

[Definisi Ketidakstabilan Mikrosatelit pada Kanker: apa yang harus diketahui](#)

[Fakultas Kedokteran Universitas Trisakti](#) [Jurnal Biomedika dan Kesehatan Vol 8 No 1 \(2025\) 98-110](#)

[2025](#) [DOI: 10.18051/JBiomedKes.2025.v8.98-110](#) [Accred : Sinta 3](#)

[Studi Banding in-vitro terakit Efikasi Antelmintik Ekstrak Daun Pegagan \(Centella asiatica\) dan Daun Putri Malu \(Mimosa pudica\) terhadap Cacing Ascaris suum](#)

[Fakultas Kedokteran Universitas Trisakti](#) [Jurnal Biomedika dan Kesehatan Vol 8 No 1 \(2025\) 35-44](#)

[2025](#) [DOI: 10.18051/JBiomedKes.2025.v8.35-44](#) [Accred : Sinta 3](#)

[Efektivitas Pemberian Probiotik Bifidobacterium longum Terhadap Pertumbuhan Pseudomonas aeruginosa Pada Mencit \(Mus musculus\)](#)

[Fakultas Kedokteran Universitas Trisakti](#) [Jurnal Biomedika dan Kesehatan Vol 8 No 1 \(2025\) 64-72](#)

[2025](#) [DOI: 10.18051/JBiomedKes.2025.v8.64-72](#) [Accred : Sinta 3](#)

[Gambaran Schizencephaly dengan Polymicrogyria pada Berbagai Magnetic Resonance Imaging \(MRI\) Sekuens](#)

[Fakultas Kedokteran Universitas Trisakti](#) [Jurnal Biomedika dan Kesehatan Vol 8 No 1 \(2025\) 73-78](#)

[2025](#) [DOI: 10.18051/JBiomedKes.2025.v8.73-78](#) [Accred : Sinta 3](#)

[Human Metapneumovirus \(hMPV\): Tantangan Baru dalam Kesehatan Global](#)

[Fakultas Kedokteran Universitas Trisakti](#) [Jurnal Biomedika dan Kesehatan Vol 8 No 1 \(2025\) 1-5](#)

[2025](#) [DOI: 10.18051/JBiomedKes.2025.v8.1-5](#) [Accred : Sinta 3](#)

[View more ...](#)