

Clinical Symptoms of Carpal Tunnel Syndrome and Its Correlation With Vitamin D Level

by Andira Larasari

Submission date: 17-Sep-2023 09:48AM (UTC+0700)

Submission ID: 2168025560

File name: dr_Andira_Larasari-2.docx (740.04K)

Word count: 4448

Character count: 24770



Clinical Symptoms of Carpal Tunnel Syndrome and Its Correlation With Vitamin D Level

Andira Larasari^{1*}, Rima Anindita Primandari¹, Andini Aswar¹, Yudhisman Imran¹

¹Neurology Departement, Faculty of Medicine, Universitas Trisakti, Jakarta Barat, Indonesia

ARTICLE INFO

Keywords:

Vitamin D Deficiency
Carpal Tunnel Syndrome
Neuropathic Pain
Electrodiagnostics Test

Corresponding author:

Andira Larasari

E-mail address:

andira.larasari@trisakti.ac.id
081519085868

All authors have reviewed and approved
the final version of the manuscript.

<https://doi.org/10.32539/BJI.v7i3.538>
(to be filled by the journal)

ABSTRACT

Carpal tunnel syndrome (CTS) is a common entrapment neuropathy of the peripheral nerves in the upper extremities that is often found in workers. Nerve conduction disorders occur due to compression of the carpal tunnel, resulting in motor and sensory symptoms in the hands and wrists. This causes clinical symptoms and characteristic neurophysiological examinations. Vitamin D is an intrinsic factor that causes CTS, which is now widely studied and is expected to play a role in the choice of CTS management. Vitamin D is important for maintaining health and has been found to have neuroprotective function. Several studies have proven the association between vitamin D deficiency and the incidence of CTS. Supplementation can improve clinical symptoms and neurophysiological features of mild to moderate CTS patients.

1. Introduction

Carpal tunnel syndrome (CTS) is a collection of sensory and motor symptoms resulting from compression of the median nerve as it passes through the carpal tunnel in the wrist.^{1,2} In the narrow and rigid carpal tunnel, there is not only the median nerve but also bones, ligaments, and tendons, so any changes that narrow the tunnel can cause pressure on the median nerve, which is the most vulnerable structure.

Nerve conduction disorders can occur when the carpal tunnel is compressed, resulting in sensory symptoms like pain, numbness, or tingling in the hand. These symptoms affect the distribution of the median nerve, specifically in the thumb, index finger, middle finger, and half of the ring finger on the radial side. Motor disorders can arise in advanced stages of CTS in the form of reduced finger skills and hand weakness, so patients have difficulty grasping.^{1,2}

Peripheral nerve compression neuropathy of the upper extremity is often caused by CTS. Research in America in 2003 found CTS as much as 3% of the adult population. The incidence of CTS amounts to 276 : 100,000 per year. and more often found in women at

the age of 40-60 years.²

The exact etiology of CTS in some cases is still unknown, especially in elderly patients. Risk factors for CTS include intrinsic factors, structural disorders or trauma factors, and hand-use factors related to hobbies or work. Intrinsic risk factors are due to systemic changes such as diabetes mellitus, rheumatoid arthritis, hypothyroidism, obesity, and pregnancy. Low levels of vitamin D are linked to CTS.²⁻⁴

Vitamin D levels are widely studied in various populations. Vitamin D deficiency is also found in countries with year-round sun exposure such as in Indonesia. Vitamin D is synthesized by the skin from 7-dehydrocholesterol with the help of ultraviolet light or obtained through diet. It plays a role in maintaining musculoskeletal health and regulating calcium-phosphorus metabolism.⁵

Vitamin D has been studied to have effects on a variety of body systems, including neuroprotective and neurotrophic function, improving nerve myelination, and inhibiting inflammation. Vitamin D deficiency is associated with nerve fibers hypersensitivity, which can cause resistant

neuropathic pain.⁶⁻⁸

Chronic pain can be caused by ⁶th Vitamin D deficiency and CTS. Studies report that ⁷itamin D deficiency is associated with CTS. Vitamin D deficiency is an independent risk factor for increased severity of CTS symptoms, especially ⁸n, tingling and nerve function.^{4,6} Increased levels of vitamin D with supplementation are expected to improve CTS symptoms.^{9,10}

2. Carpal Tunnel Syndrome

2.1. Carpal Tunnel Anatomy

CTS arises as a result of compressed median nerve within the carpal tunnel, which is located in the central part of the wrist. The bones and ligaments form a narrow tunnel through which several tendons and the median nerve pass. The bones of the carpalia form ⁹he base and sides of the hard, rigid tunnel, while ¹⁰he roof of the tunnel is formed by strong, curved retinaculum flexors.²

In the carpal tunnel there is a ⁹edian nerve that functions to channel sensation to ¹⁰he thumb, index and ring fingers and innervate the thumb muscle / famous muscle. In the tunnel there are also flexor tendons that function to move the fingers. Any condition ¹¹ results in the denser carpal tunnel can cause compression of the median nerve. The inflammatory process in the wrist can cause the tissue and protective layer of tendons around the median nerve to swell. The ligaments at the top of the carpal tunnel will thicken and enlarge, causing pressure on the medianus nerve fibers.²

2.2. Pathophysiology and Etiology

The pathophysiology of CTS is not yet known with certainty, many theories try to explain among others mechanical compression, microvascular disturbances and vibration. The causes of CTS include 3 factors, namely: (1) intrinsic factors, (2) hand use factors (related to hobbies and work), (3) structural disorders / trauma factors.²

Intrinsic factors are secondary factors due to pre-existing systemic diseases or disorders, including:

(a) Hormonal changes such as pregnancy, use of estrogen hormone in menopause.

(b) Certain diseases/conditions such as diabetes mellitus, hypothyroidism, long-lasting hemodialysis, multiple myeloma, non-Hodgkin's lymphoma, acromegaly, virus, treatment that has an effect on the immune system (interleukin 2) and anti-clotting drugs (warfarin).

(c) Overweight (obesity). The increased risk of CTS in individuals with obesity (BMI > 30) is due to increased ⁴eposition and increased hydrostatic pressure on ¹⁰he median nerve in the carpal tunnel.

(d) Other conditions such as smoking, malnutrition and stress

(e) Family history of CTS

(f) Gender. The results showed that women had a significantly higher risk of getting CTS than men.^{2,3}

Two other CTS causative factors are associated with local abnormalities in the carpal tunnel. Causes of structural disorders in the carpal tunnel include deformity of the bones that make up the carpal tunnel, scarring due to burns, degeneration and inflammatory processes in tendons, muscle abnormalities, structural abnormalities of blood vessels in the wrist, and tumors in the wrist.^{2,3}

Hand use (due to hobbies or work) can cause tenosynovial inflammation/swelling in the carpal tunnel. Example of hand use that is related to hobbies are household chores (sewing, knitting, piercing, cooking), arts and sports.²

Hand use that is related to work involves activities that are repetitive, prolonged or vigorous, which can affect both the hands and the wrists. If these potential risk factors appear simultaneously, the likelihood of CTS also increases.^{2,11}

CTS is a type of Cumulative ³trauma Disorders (CTD) with a prevalence around 50 cases per 1000 subjects in the general population. The National Health Interview Study (NHIS) estimates the prevalence of CTS as ¹1.55%. CTS is often found in industrial workers. More than 50% of occupational diseases in the USA are CTD. The most common ³pes are CTS (40%), tendosynovitis including trigger finger (32%) and De Quervan's syndrome (¹²14), and epicondylitis (20%).²

The diagnosis of CTS is established by anamnesis, special physical and neurological examination, and supported by electrophysiological examination.

2.3 ¹⁴agnosis

The diagnosis of CTS is established through patient history, specific ¹⁰ysical and neurological examination, and supported by electro-diagnostics examination.²

2.3.1. Patient History

A good history can help clinicians diagnose CTS. History includes complaints and symptoms felt by the patient, the time of occurrence, things that trigger and things that alleviate these compla¹⁵ and symptoms. These symptoms match to ¹⁰he distribution of the median nerve through the wrist and fingers. In the early stages, symptoms typically manifest as sensory disorders only before motor disorders appear, which are only present in severe cases.^{2,3,11}

2.3.2. Physical dan Neurological Examination

Specific physical and neurological examinations are required components in determining the diagnosis and severity of CTS. A complete physical examination of the upper extremities, including the neck, shoulders, elbows and wrists needs to be done to rule out a differential diagnosis. Hand and wrist inspections can provide clues about CTS risk factors, such as signs of trauma, arthritis or obesity.^{2,12}

Neurological physical examination performed is an examination of the motor, sensory and autonomic functions of the hands. During an examination of sensory function can be found hypoesthesia on the dorsal index finger compared to the little finger on the same hand, this examination has a sensitivity of 39% and specificity of 88%. Two-point discrimination abnormality can also be found, if the patient cannot distinguish 10 points at a distance of more than 6 mm in the median nerve area, the test is considered positive.^{1,12}

During an examination of autonomic function, it is observed whether there are differences in sweat, dry or slippery skin limited to the area of median nerve innervation.³ At a more severe level there are motor impairments on physical examination, among others :

1. Thenar wasting.

During an inspection and palpation can be found the presence of atrophy of the thenar muscles. The sensitivity of this examination is around 12-16% and the specificity is 90-94%.^{2,12}

2. Luthy sign.

This examination is carried out by grasping a tubular object, said to be positive if the skin fold cannot touch the surface of the object tightly.³

3. Weakness of abductor pollicis brevis muscle.

Weakness of abduction and opposition of the thumb occurs. To examine this muscle the thumb is aligned with the index finger, then the patient is asked to perform abduction movements while the examiner gives resistance to the finger. The sensitivity of this examination is around 29-65% and the specificity is 73%.¹²

Specific neurological examinations in the form of provocation maneuvers are easy to perform and can help establish the diagnosis of CTS. These tests include :

1. Tinnel Test

During Tinnel's test, examiner perform percussion of the median nerve in the wrist's distal area. Positive test results for median nerve involvement include paresthesia and discomfort in the finger innervated by the nerve. The Tinel test has a sensitivity of 36-50% and specificity of 77%.

2. Phalen Test

During Phalen test, examiner perform maximum flexion on the wrist. This action will cause pressure of the median nerve in the carpal ligament of the transverse part and flexor tendon in the carpal tunnel. This test is positive if symptoms of paresthesia and discomfort develop before one minute. Phalen test has a sensitivity of 57-68% and a specificity of 58-73%.

3. Pressure Provocation Test

Pressure provocation test is done by pressing thumb against the median nerve in the wrist transverse carpal ligament. This test will give a positive result in the form of pain, tingling, and

discomfort in the area innervated by the median nerve before 30 seconds of pression. The sensitivity of this examination is 64% with 83% specificity. The combination of the median nerve compression test and the positive Phalen test increased sensitivity to 80% and specificity to 92%.

4. Diagram of symptoms on hand (by Katz)

This examination uses a symptom diagram on the hand that shows the palmar and dorsal parts of the hand that are symptomatic of pain, numbness, tingling and divides the pattern into classic, probable, and unlikely. This examination has a sensitivity of 64-75% and a specificity of 73%.

5. Symptoms of square-shaped wrist

Kuhlman et al report a square-shaped wrist in CTS patients, where the anterior-posterior size divided by the lateral medial size of the wrist is greater than 0.7 and there is weakness of the abductor pollicis brevis muscle. The sensitivity of this examination is 53% with 80% specificity.

6. The Therede Median Nerve Stress Test

This examination is done by hyperextending the supination of the wrist and distal joints of the middle finger for one minute, patients with chronic CTS will feel pain in the volar part of the forearm. This test gave positive results in 60% of CTS patients.

7. Torniquet Test

With a blood pressure gauge attached to the arm, the measuring balloon is inflated above systolic pressure for one minute. In the positive results, symptoms of paresthesia arise in the part innervated by the median nerve. This examination is difficult to evaluate because in people with a normal median nerve the same symptoms can occur. The sensitivity of this examination is around 21%-52% with specificity of 36%-87%.

8. Hand elevation check

The patient is asked to raise his hand and hold for 60 seconds. The positive result is discomfort in the median nerve distribution area. The sensitivity and specificity of this examination is similar to the Phalen and Tinel examination, namely 75%-88% specificity and 98%-99% sensitivity.

9. Flick's sign.

The patient is asked to repeatedly flick the hand or move the finger. If their complaints decrease or disappear, it will support the diagnosis of CTS. This examination has a sensitivity of 93% and the specificity of 96%.^{2,12}

2.3.3. Electro-diagnostics Test

Support tests with electro-diagnostics including nerve conduction studies (NCS) and electromyography (EMG) are needed to confirm the diagnosis in atypical cases, determine the severity and determine surgical treatment. This test can diagnose CTS with a sensitivity of 56-85% and specificity of 94-99%. However, mild CTS patients can still have normal results in 1/3 of cases.^{2,12}

EMG test evaluates pathological changes in the muscles innervated by the median nerve. The most frequently examined muscle is the abductor pollicis brevis. This examination is indicated if there is suspicion of acute/chronic neurogenic changes and to distinguish CTS from proximal nerve entrapment, radiculopathy, or myopathy.^{2,12}

NCS test is a standard supporting examination to assess the severity of CTS by measuring the speed of conduction of sensory and motor fibers of the median nerve in the wrist. The sensitivity of this examination is 49%-84% and the specificity is 95%-99%. In entrapment neuropathy, nerve conduction is decreased due to demyelination. The assessment of the severity of CTS based on NCV examination is divided into six levels.^{2,12}

2.3.4. Other Supporting Examination

Supporting examination with ultrasound (USG) has been widely studied as an initial diagnostic support examination of CTS. Research confirms the safety, tolerance, effectiveness and accuracy of ultrasound examinations, especially high-resolution ultrasound, for the diagnosis of CTS. In research by Hernawan in 2012 obtained sensitivity and specificity of the combination of clinical features and ultrasound was 86.04% and 73.33%, with an accuracy of 82.75%. There is a compatibility between clinical combination examination and ultrasound with clinical combination and electrodiagnostic examination in detecting CTS.¹³

The advantages of ultrasound are: 1) cheaper cost, 2) noninvasive, 3) short examination time, 4) easy to find in health services 5) evaluation of etiology such as tenosynovitis, mass and tendinopathy.¹³

The ultrasound examination has limitations such as relying on the examiner's expertise, inability to rule out polyneuropathy as an etiology, and the inability to assess the severity of CTS. Experience performing ultrasound for CTS diagnosis correlates with high inter-rater reliability during examination.¹³

Ultrasound examination of CTS patients can be found images: protrusion of the retinaculum flexor, deposition in the distal median nerve, and enlargement of the median nerve diameter in the proximal flexor retinaculum. Ultrasound measurement of median nerve diameter is a recommended diagnostic tool for CTS when performed by experienced clinicians. Performing the measurement is simple and it has a high sensitivity and specificity. The diameter of the cross section of the median nerve increases significantly in CTS patients compared to the normal population, and is associated with the symptoms and severity of CTS.^{14,15}

Plain radiographic examination is performed if there are structural abnormalities such as bone and joint deformities, or in a history of acute trauma. A

plain photo of the wrist can help see if there is a fracture or arthritis. A plain photo of the neck is useful to rule out the presence of other diseases of the vertebrae. CT scan and MRI are performed in selective cases, especially those to be operated on.^{2,12}

Assessment of the severity of CTS can be done with a questionnaire based on the signs and symptoms of CTS. CTS questionnaires include Boston carpal tunnel questionnaire (BCTQ), Disabilities of the arm, shoulder and hand (DASH) outcome questionnaire, Quick Disabilities of the arm shoulder and hand (QuickDASH), Michigan Hand Outcomes Questionnaire (MHQ).¹⁶

The Boston carpal tunnel questionnaire (BCTQ) is a questionnaire that is widely used for diagnosis and research on CTS because it represents classic complaints and symptoms of CTS, is specific to CTS sufferers, and can be answered by patients themselves. The BCTQ questionnaire has been translated into Indonesian by Putra et al in 2017, and has been proven valid and reliable to be used as an instrument in assessing the severity of symptoms and functional status in CTS.¹⁶

The BCTQ questionnaire consists of two domains, namely the degree of severity of symptoms and the functional status of the hands. The symptom severity domain (SSS) consists of 11 questions covering subjective symptoms such as tingling, numbness, etc., while the functional status domain (FSS) consists of 8 questions regarding the presence or absence of interference in carrying out daily activities. Each answer has a scale of 1 to 5, where the higher the scale value indicates the severity of the symptoms. The results showed BCTQ has good reproducibility, internal consistency, validation and sensitivity in analyzing CTS.¹⁶

2.4. Differential Diagnosis

Some musculoskeletal and blood vessel disorders present with symptoms such as pain, paresthesia, sensory disturbances or weakness in the shoulders, arms and hands that are similar to CTS symptoms, including:

1. Cervical radiculopathy in the C6 or C7 region
2. Cervical spondylitis
3. Cervical polyradiculopathy
4. Brachial plexopathy
5. Neuropathy of the median nerve
6. Motor neuron diseases
7. Fibromyalgia
8. Compartment syndrome involving the hands.²

3. Vitamin D Deficiency on Carpal Tunnel Syndrome.

Vitamin D is a prohormone that plays a crucial role in calcium absorption in the digestive system. An estimated one million people in the world experience vitamin D deficiency. The age of people with deficiency also varies, ranging from children to those who are elderly. Vitamin D deficiency is more

common in countries with four season than in countries with year-round sun exposure. However, a study conducted in Jakarta, Indonesia revealed that even in a year-round sunny location, vitamin D deficiency was present in 35,1 % elderly women.⁵

Recommended range for serum Vitamin D 25 (OH) levels is 30–100 ng/mL to prevent health problems, with levels between 40–60 ng/mL are considered optimal. Vitamin D poisoning occurs when levels exceed 150 ng/mL.⁵

Vitamin D is primarily produced in the skin when it is exposed to ultraviolet B radiation, with only 10% obtained from food sources. Some food sources that contain vitamin D include oily fish like salmon, mackerel, and sardines, as well as cod liver oil, liver and egg yolks.⁵

Vitamin D deficiency can be caused by various factors, including decreased synthesis, lack of intake, decreased reserves, exclusive breastfeeding, malabsorption and increased degradation. Of the five factors, the most influential is due to a decrease in vitamin D manufacturing, including: dark skin tone, use of sunscreen and closed dressing. The darker a person's skin tone, the longer it takes to form vitamin D compared to those with lighter skin tones.⁵

In the epidermis, exposure to UV-B rays with wavelengths of 290-315 nm, causes the synthesis of 7-dehydrocholesterol (provitamin D) to pre-vitamin D. Pre-vitamin D then undergoes isomerization into vitamin D.⁵

Vitamin D is important for maintaining health. It plays a significant role in the musculoskeletal system, calcium-phosphorus metabolism, and provides protection against non-skeletal conditions such as diabetes mellitus, cardiovascular, atherosclerosis, infections, autoimmune, and malignancy. Vitamin D has also been known to have neuroprotective functions.^{5,17,18}

Vitamin D in the form of D2 (ergocalciferol), and D3 (cholecalciferol) have neuroprotective and neurotrophic functions. It has the ability to accelerate axon regeneration by enhancing nerve myelination and increasing production of nerve growth factor. Vitamin D deficiency is also associated with hypersensitivity of nerve fibers that can lead to resistant neuropathic pain. Vitamin D receptors are found on peripheral nerves and Schwann cells. In addition to its function in nerve tissue, vitamin D also plays a role in inhibiting vascular endothelial growth factor (VEGF) associated with fibrosis due to inflammation, which can trigger CTS.⁶⁻⁸

CTS and vitamin D deficiency are both conditions that can cause chronic pain. Vitamin D deficiency is an independent risk factor for increased severity of CTS symptoms, especially pain, tingling and nerve function. Symptoms of CTS can be triggered by low levels of vitamin D. Some studies suggest low vitamin D levels are associated with the incidence of

CTS. Abdul Razak et al research stated that 95.8% of patients with CTS had vitamin D deficiency compared to 22.9% of controls.¹⁹

Lee et al study in women with CTS provided the results of CTS women under the age of 50 having significantly lower vitamin D levels than age-appropriate healthy control women (P = 0.023).²⁰

The Demiryurek & Gundogdu study on 76 normal and mild CTS subjects gave significantly lower vitamin D levels than subjects with normal neurophysiological outcomes (P = 0.003). Vitamin D deficiency increases pain intensity in CTS patients.⁶

Vitamin D supplementation has been studied to improve outcomes in the management of CTS. Increased levels of the vitamin D can improve CTS symptom such as pain, numbness, improve functional status, and increase sensory nerve conduction rate.^{9,10}

In multiple studies, vitamin D supplementation, significant CTS symptoms assessed by VAS and pain DETECT were significantly reduced.^{18,21,22} Functional improvement with DASH and BCTQ examination showed improvement after vitamin D supplementation.^{20,22,23} There is no difference between motor strength and motor conduction speed of the median nerve. However, there was an improvement in the speed of sensory conduction of the median nerve.^{20,21}

Various studies have indicated that vitamin D supplementation for minimum 12 weeks can alleviate pain, improve hand function and improve the results of neurophysiological examination in individuals with mild to moderate symptoms of CTS. However, there is currently no recommended dose or duration for the use of vitamin D supplements in CTS. The current recommendation is to add a daily dose of vitamin D as an addition to CTS management while monitoring vitamin D levels.^{7,18}

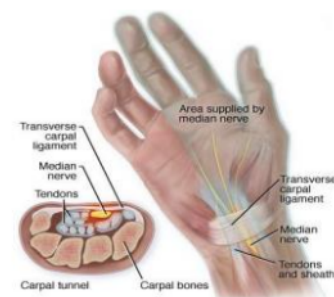


Figure 1. The anatomy of Carpal Tunnel²

4. Conclusion

CTS is a neurological disorder that can affect the quality of life. Diagnosis and assessment of severity are important for the assessment of successful management and monitoring of the patient's functional body. Vitamin D is an intrinsic factor that causes CTS which is now widely studied and is expected to play a role in the choice of CTS management. Several studies have proven the association of vitamin D deficiency and the incidence of CTS. Supplementation can improve clinical symptoms and neurophysiological features of mild to moderate CTS patients, but there is no specific recommendation for vitamin D for neuropathic pain, especially CTS.

This literature review is expected to be a literature material for further research and learning related to CTS. In future studies, optimal levels and doses of vitamin D can be examined in neuropathic pain patients, especially in CTS.

5. References

1. Ghasemi-Rad M, Nosair E, Vegh A, Mohammadi A, Akkad A, Leshia E, et al. A handy review of carpal tunnel syndrome: From anatomy to diagnosis and treatment. *World J Radiol*. 2014 Jun 28;6(6):284–300.
2. Salawati L, Syahrul S. Carpal Tunnel Syndrome. *Jurnal Kedokteran Syiah Kuala*. 2014;14(1):29–37.
3. Padua L, Coraci D, Erra C, Pazzaglia C, Paolasso I, Loreti C, et al. Carpal tunnel syndrome: clinical features, diagnosis, and management. *Lancet Neurol*. 2016 Nov;15(12):1273–84.
4. Tanik N, Balbaloğlu Ö, Ucar M, Sarp U, Atalay T, Çelikkilek A, et al. Does vitamin D deficiency trigger carpal tunnel syndrome? *J Back Musculoskeletal Rehabil*. 2016 Nov 21;29(4):835–9.
5. Pusparini. Defisiensi Vitamin D Terhadap Penyakit. *Indonesian Journal Of Clinical Pathology And Medical Laboratory*. 2014 Nov 1;21(1):90–5.
6. Demiryurek BE, Gundogdu AA. The effect of vitamin D levels on pain in carpal tunnel syndrome. *Orthop Traumatol Surg Res*. 2017 Oct;103(6):919–22.
7. Anusitviwat C, Suwanno P, Suwannaphisit S. The effects of vitamin D supplementation in carpal tunnel syndrome treatment outcomes: a systematic review. *J Exp Orthop*. 2021 Sep 7;8:73.
8. Kuru P, Akyuz G, Yagci I, Giray E. Hypovitaminosis D in widespread pain: its effect on pain perception, quality of life and nerve conduction studies. *Rheumatol Int*. 2015 Feb;35(2):315–22.
9. Özer G. The impact of serum vitamin D concentration on median nerve conduction. *J Clin Exp Invest [Internet]*. 2018 Jun 13 [cited 2023 Sep 16];9(2). Available from: <http://www.jceionline.org/article/the-impact-of-serum-vitamin-d-concentration-on-median-nerve-conduction-3820>
10. Nageeb RS, Shehta N, Nageeb GS, Omran AA. Body mass index and vitamin D level in carpal tunnel syndrome patients. *Egypt J Neurol Psychiatr Neurosurg*. 2018;54(1):14.
11. Chammas M, Boretto J, Burmann LM, Ramos RM, dos Santos Neto FC, Silva JB. Carpal tunnel syndrome – Part I (anatomy, physiology, etiology and diagnosis). *Rev Bras Ortop*. 2014 Aug 20;49(5):429–36.
12. Wiperman J, Goerl K. Carpal Tunnel Syndrome: Diagnosis and Management. *afp*. 2016 Dec 15;94(12):993–9.
13. Hernawan A. Tingkat sensitivitas dan spesifisitas kombinasi gambaran klinis dan Ultrasonografi untuk diagnosis Sindroma Terowongan Karpal di Rumah Sakit Cipto Mangunkusumo [Internet]. Universitas Indonesia Library. Fakultas Kedokteran Universitas Indonesia; 2012 [cited 2023 Sep 16]. Available from: <https://lib.ui.ac.id>
14. Kapuścińska K, Urbanik A. High-frequency ultrasound in carpal tunnel syndrome: assessment of patient eligibility for surgical treatment. *J Ultrason*. 2015 Sep;15(62):283–91.
15. Klauser AS, Halpern EJ, De Zordo T, Feuchtner GM, Arora R, Gruber J, et al. Carpal tunnel syndrome assessment with US: value of additional cross-sectional area measurements of the median nerve in patients versus healthy volunteers. *Radiology*. 2009 Jan;250(1):171–7.
16. Yoga Putra A. Uji validitas dan reliabilitas kuesioner Boston Carpal Tunnel Syndrome Questionnaire (BCTQ) versi bahasa Indonesia [Internet]. Universitas Indonesia Library. Fakultas Kedokteran Universitas Indonesia; 2018 [cited 2023 Sep 16]. Available from: <https://lib.ui.ac.id>
17. Imran Y, Aswar A, Rachmiyani I, Adriani D. Low

- 25-hydroxyvitamin D level increases carotid intima-media thickness in elderly women. *Universa Medicina*. 2019;38:114–20.
18. Yalçın Ü, Badıl Güloğlu S. The Effect Of Vitamin D Treatment On Neurophatic Pain And Functional Activity In Patients With Carpal Tunnel Syndrome. *Global Journal For Research Analysis*. 2021 May 15;234–7.
 19. Abdul-Razzak KK, Kofahi RM. Carpel tunnel syndrome: A link with vitamin D and calcium. *Biomed Rep*. 2020 Sep;13(3):15.
 20. Lee SH, Gong HS, Kim DH, Shin HS, Kim KM, Kim J, et al. Evaluation of vitamin D levels in women with carpal tunnel syndrome. *J Hand Surg Eur Vol*. 2016 Jul;41(6):643–7.
 21. Saçmacı H, Tanık N, Balbaloglu Ö, Aktürk T, Inan LE. Electrophysiological evaluation of carpal tunnel syndrome female patients after vitamin D replacement. *Arq Neuropsiquiatr*. 2020 Apr;78(4):224–9.
 22. Samant PD, Sane RM. Evaluation of Functional and Symptomatic Outcomes After Vitamin D3 Administration in Carpal Tunnel Syndrome With Hypovitaminosis D. *Hand (N Y)*. 2022 Nov;17(6):1065–9.
 23. Mohtashamkia M, Roshanzamir S, Saghanezhad SM. Vitamin D in Treatment-Resistant CTS Patients with Hypovitaminosis D. *JCDR*. 2018 Jul;12(7):LC23-26.

Clinical Symptoms of Carpal Tunnel Syndrome and Its Correlation With Vitamin D Level

ORIGINALITY REPORT

14%

SIMILARITY INDEX

12%

INTERNET SOURCES

11%

PUBLICATIONS

4%

STUDENT PAPERS

PRIMARY SOURCES

1	jeo-esska.springeropen.com Internet Source	2%
2	tessera.spandidos-publications.com Internet Source	1%
3	www.jurnal.unsyiah.ac.id Internet Source	1%
4	knowledgecommons.lakeheadu.ca Internet Source	1%
5	medicine.uodiyala.edu.iq Internet Source	1%
6	"Vitamin D in Chronic Kidney Disease", Springer Nature, 2016 Publication	1%
7	www.frontiersin.org Internet Source	1%
8	Shigeharu Uchiyama. "Current concepts of carpal tunnel syndrome: pathophysiology,	1%

treatment, and evaluation", Journal of
Orthopaedic Science, 01/2010

Publication

9

"Carpal Tunnel Syndrome and Related Median Neuropathies", Springer Science and Business Media LLC, 2017

Publication

1 %

10

lup.lub.lu.se

Internet Source

1 %

11

experimentalbiomedicalresearch.com

Internet Source

1 %

12

Submitted to City University

Student Paper

1 %

13

bji-fk.ejournal.unsri.ac.id

Internet Source

1 %

14

e-arm.org

Internet Source

<1 %

15

Seok Kang, Seung Nam Yang, Joon Shik Yoon, Hyo Jeong Kang, Sun Jae Won. "Effect of Carpal Tunnel Syndrome on the Ulnar Nerve at the Wrist", Journal of Ultrasound in Medicine, 2016

Publication

<1 %

16

jddtonline.info

Internet Source

<1 %

17 "Indian Society of Gastroenterology", Indian Journal of Gastroenterology, 2015 <1 %
Publication

18 Michael S. Cartwright. "Evidence-based guideline: Neuromuscular ultrasound for the diagnosis of carpal tunnel syndrome", Muscle & Nerve, 2012 <1 %
Publication

19 Submitted to Sriwijaya University <1 %
Student Paper

20 C. H. S. Ruxton. "Health impacts of vitamin D: are we getting enough?", Nutrition Bulletin, 06/2009 <1 %
Publication

21 Submitted to Divine Child High School <1 %
Student Paper

Exclude quotes Off
Exclude bibliography On

Exclude matches < 15 words